University of Nebraska Medical Center

MRI in Neuro-Oncology

Matthew L. White, MD

Nebraska Medicine

BRAIN AND SPINE CANCER CENTER

Neuroimaging Oncology

- Review Basics of Brain Imaging
  - Contrast agent
  - MRI choice
- Advanced MRI applications in neuro-oncology
  - Diffusion Imaging- microstructure brain or tumor
  - Perfusion Imaging – blood flow/blood volume
  - Spectroscopy – chemical signature
  - fMRI and tractography

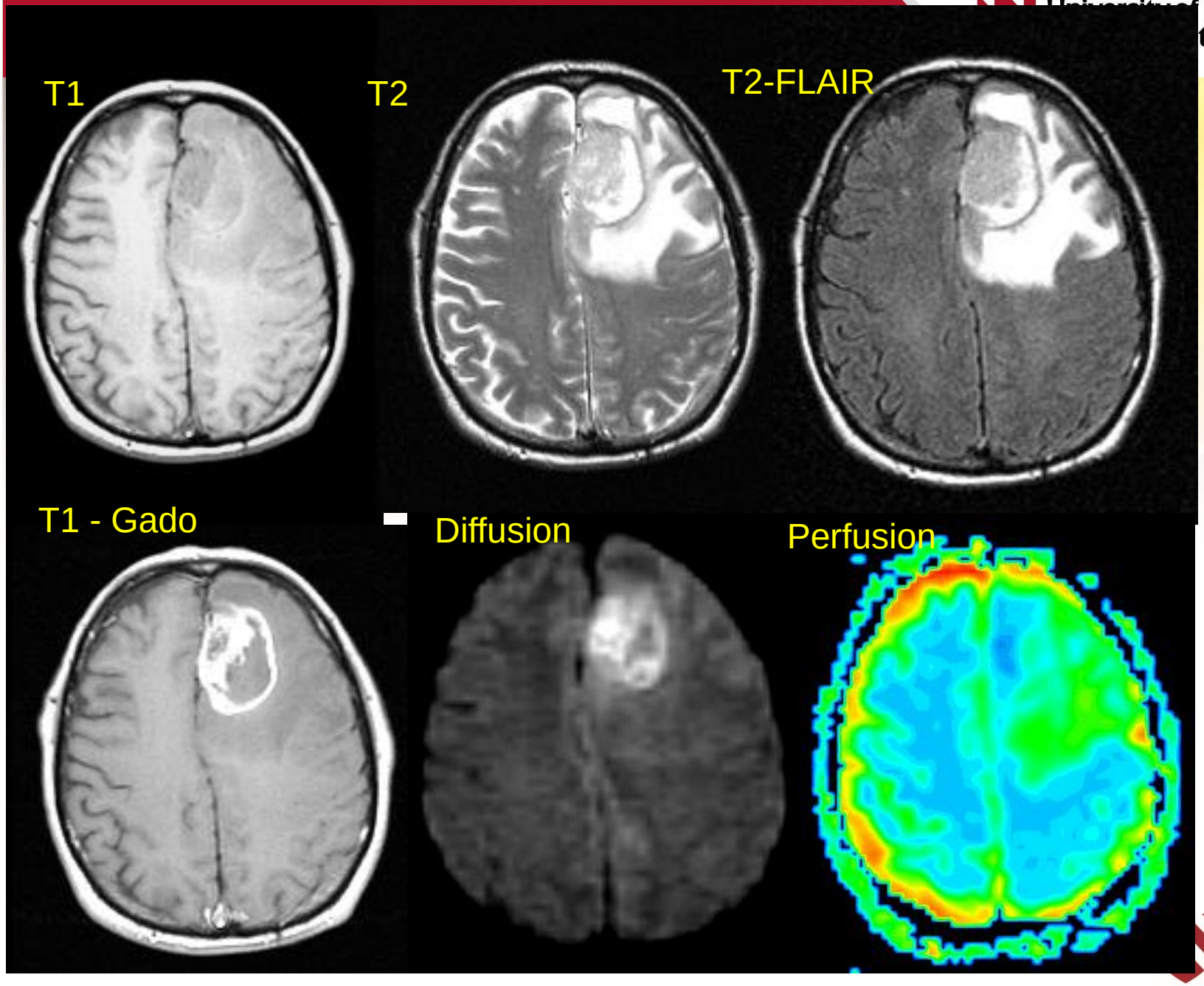

Path dx = GBM

Nebraska Medicine
BRAIN AND SPINE CANCER CENTER

Gadolinium agents

- T1-shortening
  - Creates high signal
- Demonstrates enhancement due to blood brain barrier(BBB) breakdown
- DELAYED STATIC ENHANCEMENT
  - Inject IV contrast and then obtain T1 image
  - What type of T1, What type of contrast
- Gadolinium agent first approved in 1988

Nebraska Medicine
BRAIN AND SPINE CANCER CENTER

TIPS:
How to image – neuro-oncology

- 3T potential advantage over 1.5T
- What contrast agent to use
- T1 relaxivity - ENHANCEMENT
  - Multihance > Gadavist > others
  - Others= Magnevist, Prohance, Omniscan, Dotarem
- Volumetric imaging
  - 1 acquisition and can look at brain in many planes
    - Axial, sagittal, and coronal

Utility of Enhancement

- Lesion detection
  - Can perform contrast images with high resolution!
- Enhancement can help to indicate grade of tumor - but not perfect NEED PATHOLOGY
- Low grade Astrocytoma and Oligodendroglioma
  - No enhancement
    - (EXCEPTIONS – pilocytic astrocytoma, ganglioglioma, PXA, DNET)
- Anaplastic Astrocytoma and Oligodendroglioma
  - Enhancement
- Metastatic disease
  - Enhance

Ring Enhancing Lesions

- Tumors
  - primary brain tumor
  - metastatic tumor
- Abscess
  - single or multiple
- Multiple Sclerosis
- Subacute stroke
- Hematoma
- Radiation necrosis
- AIDS – toxoplasmosis, lymphoma
- Lymphoma – immunosuppresd (non-AIDS)

Utility of Enhancement

- 60 subjects, MRI exams with contrast
- Enhanceme ost-contrast
  - To avoid su nhancement
- 80% of tumo s enlarged from enhancing n
- **Markedly su rmance vs CT**

CT good for :
Hemorrhage
Fractures
Mass effect

Early Postoperative Magnetic Resonance Imaging after Resection of Malignant Glioma: Objective Evaluation of Residual Tumor and Its Influence on Regrowth and Prognosis
Albert, Friedrich K. M.D.; Forsting, Michael M.D.; Sartor, Klaus M.D.; Adams, Hans-Peter D.-I.M.; Kunze, Stefan M.D.
Neurosurgery 1994

Utility of Diffusion MRI



Many cells will cause slow water motion and restricted diffusion.



Few cells with non-restricted diffusion.

Diffusion analysis confounded:

Hemorrhage

Edema

Necrosis

Inflammation

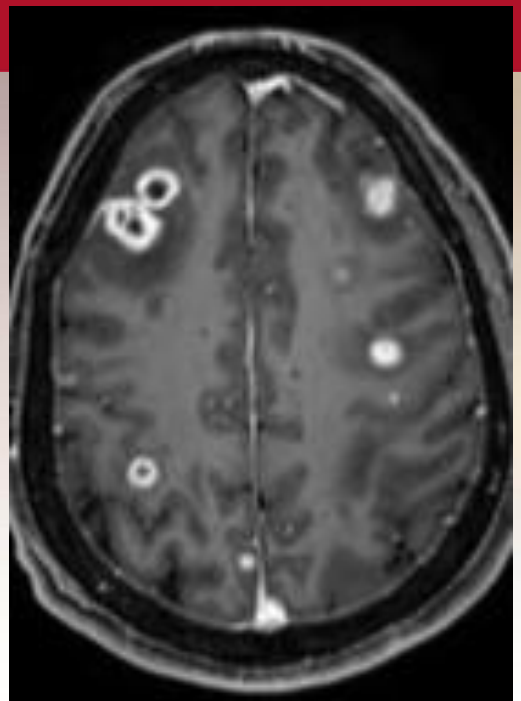

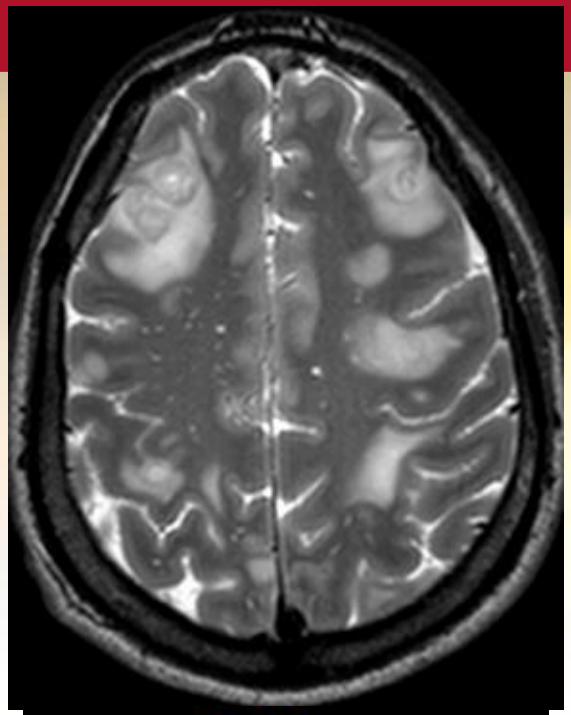

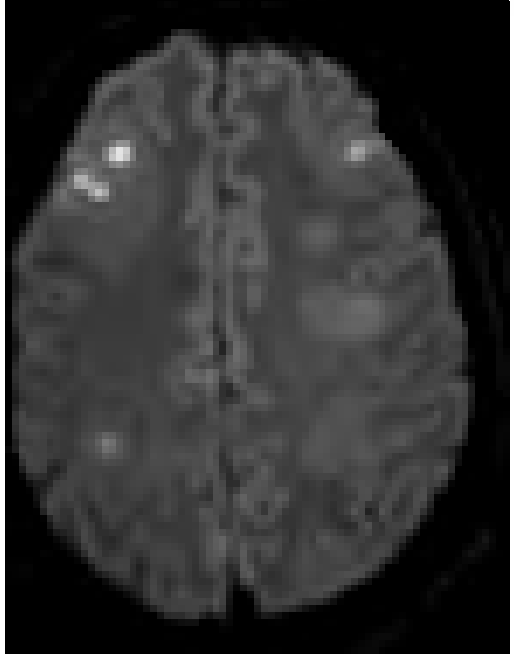

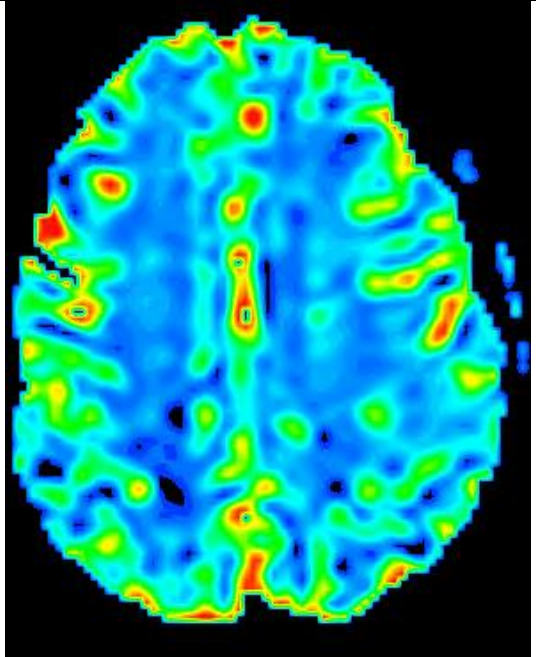

Multiple abscesses with:

1) High diffusion centrally
2) No elevated perfusion

History: 35 y.o. male feeling poorly with fever, fatigue, and headaches for a couple of weeks.

Path: Abscess wall and microbiology demonstrated streptococcus viridans.

Utility of Perfusion MRI

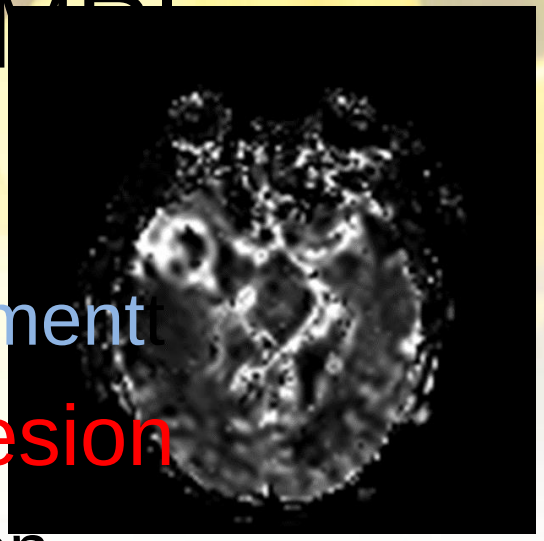

GBM

- Evaluate angiogenesis
  - Increased perfusion ≠ enhancement
- Help determine etiology of a lesion
  - GBM/AA and MET high perfusion
  - Lymphoma, demyelination and to a lesser degree abscesses – have **low** perfusion
- **Determine treatment effect vs tumor**
  - Treatment necrosis has LOW perfusion
- Oligodendrogliomas can have high perfusion

- To quantitatively measure CBV or CBF, regional changes in signal intensity versus time must be converted into contrast agent concentration-time curves.
- for a given TE, T2 rate change ($\Delta(1/T2^*)=\Delta R2$) is proportional to brain tissue contrast concentration [conc.], i.e.

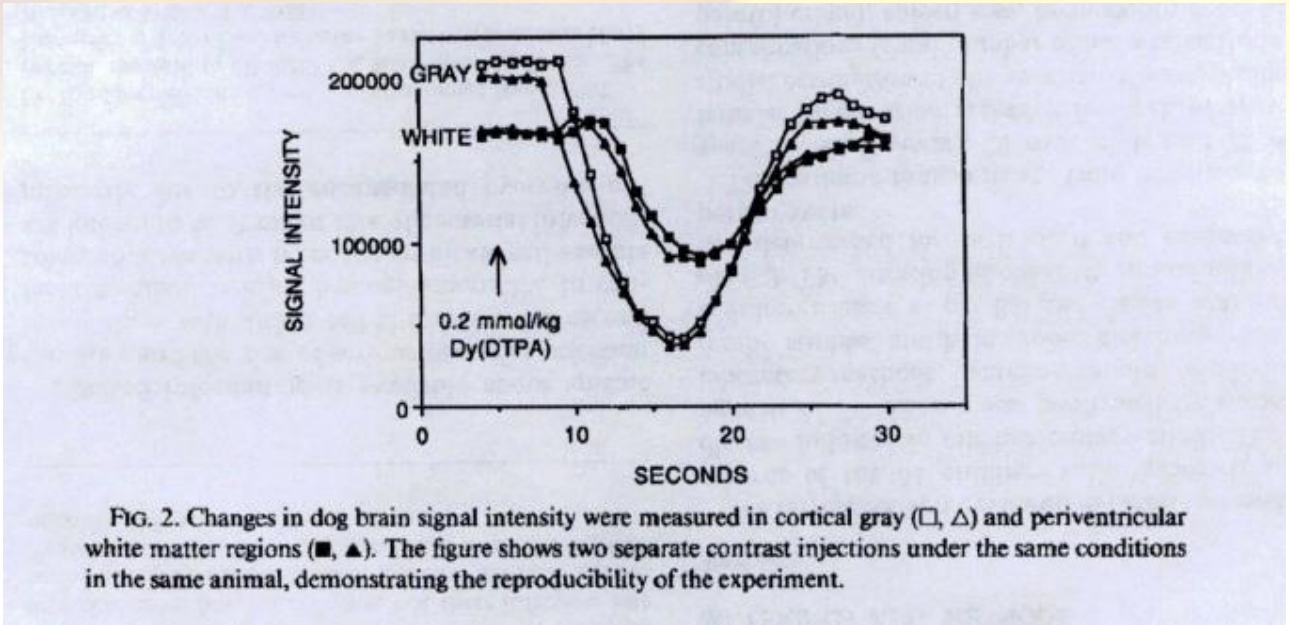

FIG. 2. Changes in dog brain signal intensity were measured in cortical gray (□, △) and periventricular white matter regions (■, ▲). The figure shows two separate contrast injections under the same conditions in the same animal, demonstrating the reproducibility of the experiment.

Belliveau JW, Rosen BR, Kantor HL, et al. Functional cerebral imaging by susceptibility-contrast NMR. Magn Reson Med 1990; 14:538-546.

$$\Delta R2 = k[\text{conc.}]$$

Where k is a tissue-, pulse sequence-, and field strength-specific constant.

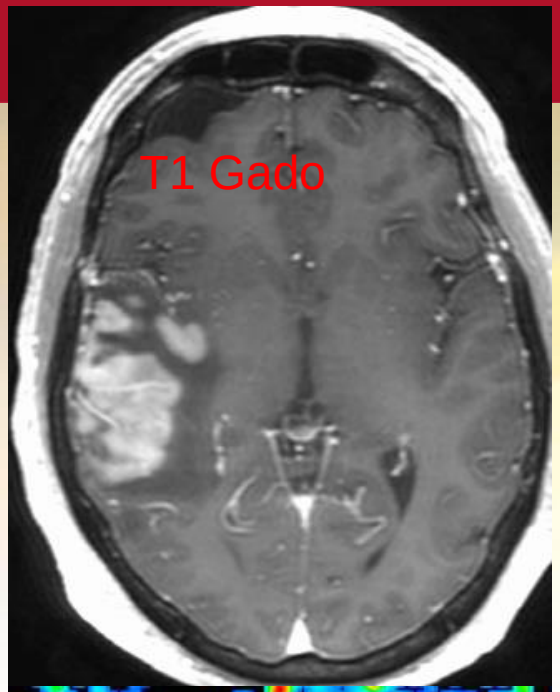

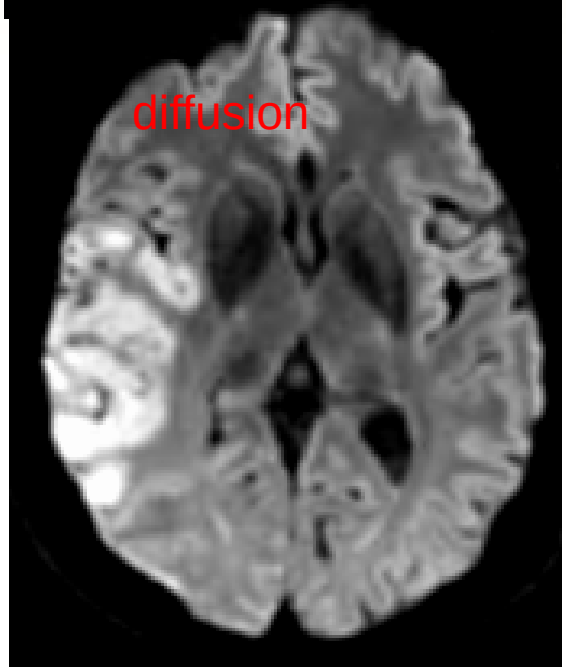

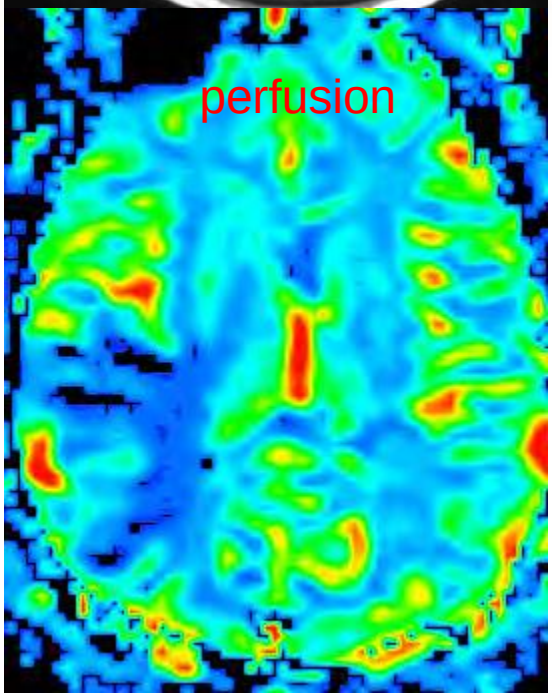

Leukemic infiltration at biopsy

CBF map – very low perfusion

- Is
- P

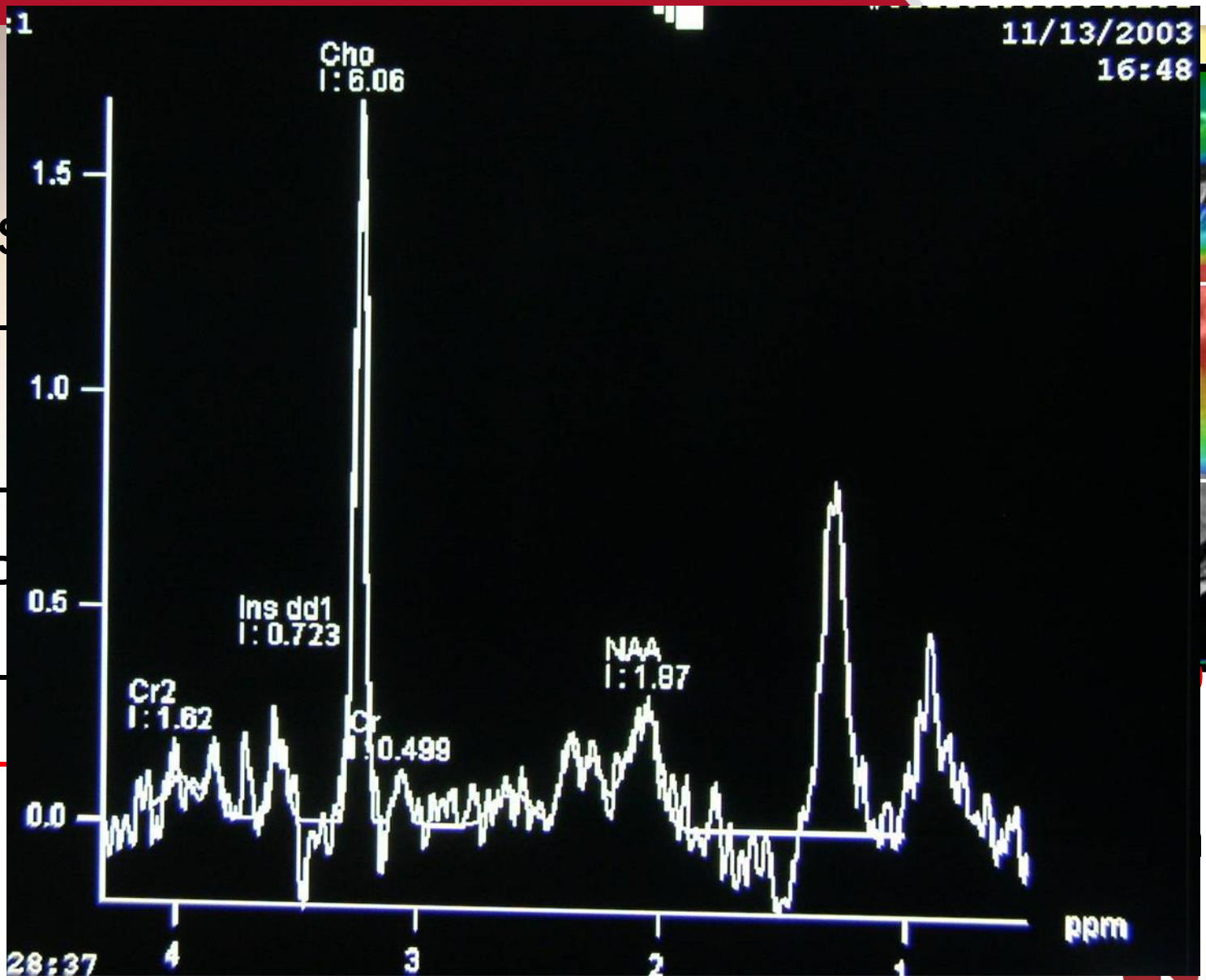
:1
11/13/2003
16:48
Cho
I: 6.06
1.5
1.0
0.5
0.0
Ins dd1
I: 0.723
Cr2
I: 1.62
Cr
0.499
NAA
I: 1.87
28:37
4
3
2
1
ppm

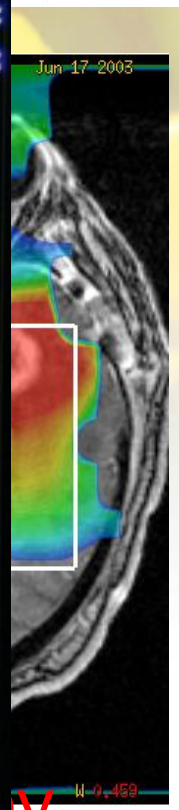
Jun 17 2003

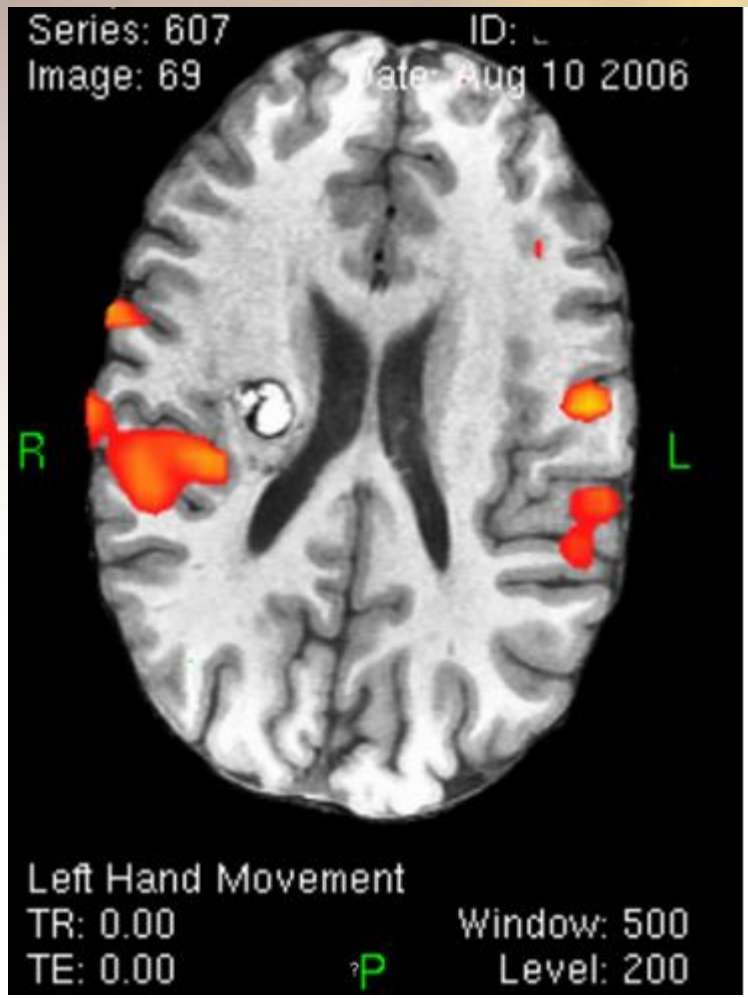

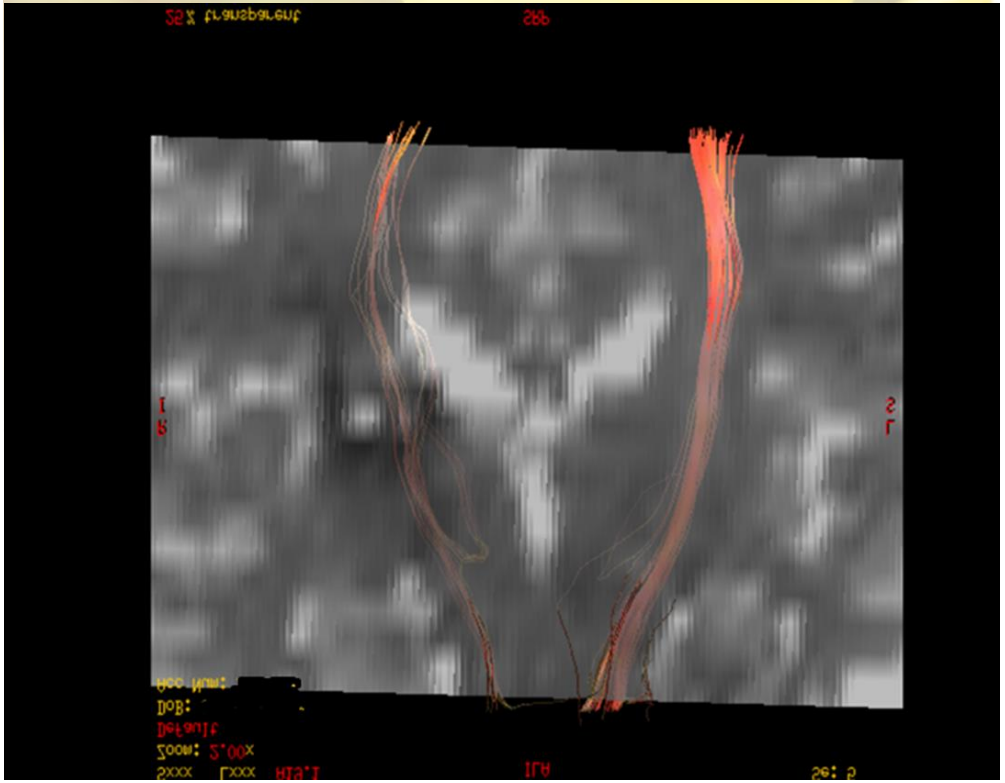

20 y.o. male developing left sided weakness, clumsiness and mild spasticity.

Brain Mapping

- fMRI
  - Vision
  - Sensory
  - Motor
  - Language
    - Word generation
      - yellow
    - Object naming
    - Word mapping
    - Verb generation
    - Passive listening
- White Matter Tracts
  - Optic radiation, vision
  - Thalamocortical, sensory
  - Corticospinal, motor
  - Arcuate fasciculus, language

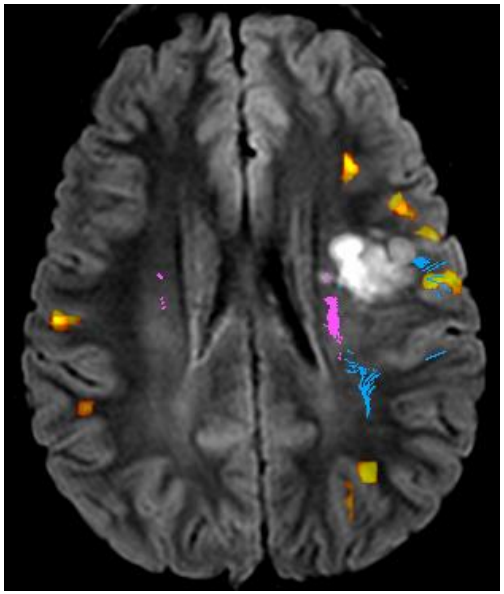

- Thank You!

- Matthew L. White, MD
- Neuroradiology